



Second report

**Effects of VigRX on Sexual Behavior, Erect Penile Size,
Intracavernous Pressure, Testosterone Level, Sperm Density,
and Some Organs in Male Sprague Dawley Rats and Its
Long - Term Effects**

Investigators:

Yuthana Smitasiri

Chainarong Tocharus

Sitthisak Pinmongkholgul

Submitted to:

Dr. Alexander Schauss, PhD, FACN

AIBMR Life Sciences, Inc.

Nov. 30 , 2005



Second report

**Effects of VigRX on Sexual Behavior, Erect Penile Size,
Intracavernous Pressure, Testosterone Level, Sperm Density,
and Some Organs in Male Sprague Dawley Rats and Its
Long - Term Effects**

Investigators:

Yuthana Smitasiri

Chainarong Tocharus

Sitthisak Pinmongkholgul

Submitted to:

Dr. Alexander Schauss, PhD, FACN

AIBMR Life Sciences, Inc.

Nov. 30 , 2005

Abstract

The aim of this project was to investigate the long-term effects of VigRX on sexual behavior at 4, 8 and 12 - week of treatment, and on erect penile size, intracavernous pressure, testosterone level, sperm density, blood chemistry and some blood parameters, and related reproductive , other organ changes at 12 - week of treatment, in the adult male Sprague-Dawley rats.)

It was found that VigRX at the dosage of 15 mg/kg/rat/day fed to male rats for 4 , 8 and 12 weeks had no effect on the body weight gained and on sexual behavior of the male rats except ejaculation latency which was significantly less than the control group .

Long term treatment of VigRX for 12 weeks could significantly increase the sperm density , the width of erect penile size and intracavernous pressure but had no effect on every organs weight i.e. penis , testes , epididymis, seminal vesicle , prostate gland , liver , kidney , adrenal gland , spleen and pituitary gland.

Long term treatment of VigRX did not have any effect on blood chemistry value, some blood parameters except the percentage of lymphocyte but long term treatment of VigRX could significantly increase the testosterone level in these rats.

Histopathological section of some organs i.e. liver , kidney and testes revealed that long term treatment of VigRX had no pathological effects on these three organs.

It was concluded that long term treatment of VigRX at the dosage of 15 mg/kg/D had no effect on body weight gained and VigRX could not induce the sexual behavior at 4 , 8 and 12 – week of treatment . Long term treatment of VigRX could significantly increase the width of erect penile size , sperm density , intracavernous pressure and testosterone level but had no effects on every organs weight , blood chemistry and some blood parameters in the male rats. Long term treatment of VigRX had no pathological effects on liver, kidney and testes histology.

Introduction

Some adult men wish to maintain or enhance erectile function, size of erect penis, and level of sex drive. It is reported that some medicinal plants improve sex performance, such as *Butea superba* (Anusarnsunthorn, 1931). Research on *Butea superba* extract has revealed that it can induce penile erection in the rat by increasing intracavernous pressure (Unpublished. Smitasiri et al, 2003; Tocharus et al, 2002), and significantly increase sperm density in the rat (Smitasiri et al, 2003), without affecting prostate gland size or weight (Kheowmung et al, 1992).

The rat is a suitable model for the study of penile erection (Quinlan et al, 1989), and can be used to study the effects of medicinal plants on sexual behavior (Ang and Ngai, 2001; Carro – Juarez et al, 2004; Gauthaman and Adaikan, 2005; Islam et al, 1991; Ramachandran et al, 2004; Tajuddin et al, 2004).

There are many kinds of medicinal plant which have been reported for their aphrodisiac effects such as Yohimbe bark, *Muira puama* root, Catuaba bark (Antunes et al, 2001), Damiana leaf, *Tribulus terrestris* (Gauthaman and Adaikan, 2005), *Syzygium aromaticum* (Tajuddin et al, 2004), *Montanoa tomentosa* (Carro – Juarez et al, 2004), *Butea frondosa* (Ramachandran et al, 2004), *Passiflora incarnata* (Dhawan et al, 2003) and *Eurycoma longiflora* (Ang and Ngai, 2001). Some medicinal plants are also noted for abilities to enhance mental alertness and stimulate circulation, such as Ginkgo leaf; improve blood flow, such as Hawthorn berry; achieve anti-oxidant effect, such as Ginkgo leaf and Panax Ginseng root; stimulate the immune system, such as Panax Ginseng root; and have tonic effect, such as Saw Palmetto berry, Panax Ginseng root, and Catuaba bark.

This study is to investigate whether and to what extent an herbal product that contains not just one but various botanical ingredients can improve erectile function, erect

penis size, and sex drive. VigRX is a product that contains Asian ginseng root, Saw palmetto berry, *Ginkgo biloba* leaf, Hawthorn berry, Muira pauma bark extract, Catuaba bark extract, Cuscuta seed extract, and Epimedium leaf extract. It is claimed that this product may induce these effects.

Aim of the project

The aim of this project is to investigate:

The long-term effects of VigRX on sexual behavior at 4, 8 and 12-weeks of treatment, and on erect penile size, intracavernous pressure, testosterone level, sperm density, blood chemistry and some blood parameters, and some organs change at 12 weeks of treatment, in the adult male Sprague-Dawley rats.

Materials and Methods

1. Preparation of VigRX for testing in rats.

1.1 VigRX bottles from U.S.

1.2 VigRX will be mixed with distilled water at the dosage of 15 mg. VigRX/kg /rat/day (Calculate from the recommended dose of VigRX for human : 2 capsules/70kg/day).

2. The laboratory rats

Adult male and female rats

The adult male and female rats of Sprague Dawley strain will be used in this study. The body weight of adult male is 250-280 grams and the body weight of 3 sets of female rats are 200-240 grams, to assay sexual behavior, erect penile size,

intracavernous pressure, testosterone level, sperm density and some organs in rats treated with VigRX.

Note: All of the rats will be supplied by the National Laboratory Animal Center, Mahidol University and transferred to Mae Fah Luang University by air.

3. Rearing of the laboratory rats

All of the laboratory rats are reared in the Animal House of Mae Fah Luang University at the ratio of one rat per cage (stainless steel cage, 8x8x12 inches), in a temperature-controlled room approximately 24 ± 1 degrees Centigrade in a room with proper ventilation and a daily light cycle of 12 h light and 12 h dark. All of the rats are fed with rodent feed #082 (Pokkapan Animal Feed Co. Ltd.). During the whole period of the study, sufficient water is provided to these rats *ad libitum*.

4. Rat groupings

Adult male and female rats for long term treatment

All of these rats are allowed to recover in the Animal House for 6 days, then weighed and recorded.

The rats are divided into 2 groups (12 rats/group).

Group 1 Receives 1 ml of distilled water administered orally fed/day for 84 consecutive days (12 weeks).

Group 2 Same as the control group but receives VigRX at the dosage of 15 mg/kg/rat/day for 84 consecutive days (12 weeks)

Each rat is weighed every 7 days until the test is completed on Day 84.

During rat treatment, on Day 28 (4-week), Day 56 (8-week) and Day 84 (12-week), between 7.00 – 9.00 p.m., the sexual behavior of each adult male rat is observed by using the in-heat female rats (Islam et al , 1991)

The sexual behavior of the male rats that will be recorded are

1. Mount latency (ML): the time interval between the introduction of the female and the first mount by the male,
2. Intromission latency (IL): the interval from the time of introduction of the female to the first intromission by the male (characterized by pelvic thrusting and springing dismount),
3. Ejaculation latency (EL): the interval from the time of introduction of the female to the first ejaculation.
4. Mounting frequency (MF): the number of mounts with intromission from the time of introduction of the female until ejaculation,
5. Intromission frequency (IF): the number of intromissions from the time of introduction of the female until ejaculation,
6. Ejaculation frequency (EF): the number of ejaculation (characterized by longer, deeper pelvic thrusting and slow dismount followed by a period of inactivity),

When the observation of the male rat's behavior is finished, each adult male rat is moved back into its own cage.

On Day 85, after the rat is weighed, penile size is measured while erect using the method of Pinmongkholgul (2001). Then the rat is anaesthetised with nembutal injected intraperitoneally. When the rat is completely anaesthetised, the intracavernosal pressure is recorded by the Maclab instrument using the method as described by Tocharus et al (2002). After recording the intracavernosal pressure, blood is collected via cardiac puncture to measure the testosterone level by the electrochemical luminescence (ECL) method, in addition to gathering blood chemistries (i.e. SGOT, SGPT, alkaline phosphatase, creatinine, BUN, cholesterol, triglyceride, total protein, albumin, glucose) and some blood parameters. The testes, epididymis, prostate gland, seminal vesicle,

pituitary gland, adrenal gland, liver, kidney and spleen are removed and weighed using a 4-digital electronic balance (Mettler: Toledo AB 204-S).

According to the epididymis, and after weighing, the cauda epididymis is removed and sperm density is counted using the method as described by Pimmongkhogul (2001).

Some organs i.e. liver, kidney and testes will be sectioned for histopathological studies.

Liver : the histopathological signs will focus on 5 parameters i.e. fatty degeneration, hepatocyte megalocytosis, lymphoid aggregated periportal area, bile duct proliferation and peliosis hepatitis.

Kidney : the histopathological signs will focus on 3 parameters i.e. multifocal tubular cyst, tubular cast and tubulonephrosis.

Testes, the histopathological signs will focus on 3 parameters i.e. interstitial edema, seminiferous tubule degeneration and congestion.

All collected data will be statistically analyzed using ANOVA and LSD.

Definition of the pathological signs for

Liver

1. Fatty degeneration : Abnormal formation of microscopically visible droplets of fat in the cytoplasm of cells, as a result of injury.
2. **Hepatocyte megalocytosis : The enlargement of hepatocyte in the liver.**
3. Lymphoid aggregated periportal area : The lymphoid tissue aggregated in the portal triad of the liver.
4. Bile duct proliferation : The elongation of bile duct in the liver.
5. Peliosis hepatitis : A rare condition in which the liver has numerous small blood-filled spaces, sometimes lined with endothelium; it may be found incidentally or rupture may cause intraperitoneal haemorrhage.

Kidney

1. Multifocal tubular cyst : A cyst formed by the dilation of any occluded canal or tube.
- 2 . Tubular cast : Tubules in the kidneys secrete proteins. Under some circumstances , these proteins precipitate out to form little cylindrical impressions of the tubules called casts.
3. Tubulonephrosis : A cyst formed by the dilation of collecting duct in the kidney.

Testes

1. Interstitial cell edema : The presence of abnormally large amounts of fluid in the intracellular tissue spaces of interstitial cell.
2. Seminiferous tubule degeneration : The degeneration of spermatogenesis in the seminiferous tubule.
3. Congestion : Excessive or abnormal accumulation of blood in a part.

Note: All experiments are approved by the board authorized by the university to regulate the use of laboratory animals for experiments.

Results

There was no significant difference between the weight gained of the male rats treated with VigRX every 7 days for 12 weeks compared with the control group (Table 1 , Fig . 1)

Studies on the sexual behavior of the male rats treated with VigRX for 4, 8, and 12 weeks revealed that there was no significant difference between the sexual behavior of the VigRX group and the control group (Table 2 - 4 , Fig . 2 – 10) except the ejaculation latency of VigRX was significantly less than the control group in only 12 – week treatment (Table 4)

VigRX could significantly increase the sperm density and the width of the erect penile size of the rat (Table 5 , Fig. 11 - 14). VigRX could also significantly increase the intracavernosal pressure (ICP) of the rat (Table 6 , Fig.15).

VigRX had no effect on the body weight and every organ studied i.e. penis , testes , epididymis , seminal vesicle , prostate gland , liver , kidney , adrenal gland , spleen and pituitary gland (Table 7).

Studies on the long term effects of VigRX (Table 8) on blood chemistry value , some blood parameters and testosterone level in the male rats , it was found that VigRX had no effect on blood chemistry value i.e. glucose , blood urea nitrogen (BUN) , creatinine , cholesterol , triglyceride , serum glutamic oxaloacetic transferase (SGOT) , serum glutamic pyruvate transferase (SGPT) , alkaline phosphatase , total protein , albumin levels (Table 8).

**Table 1 Weight gained of the male rats treated with VigRx for 12 weeks
compared with the control group**

Day 1 - Day____	Weight gained (g.)	
	Control	VigRx 15 mg
Day8	63.17 \pm 9.36	57.17 \pm 15.30
Day15	100.92 \pm 13.98	92.67 \pm 15.41
Day22	127.67 \pm 17.20	118.17 \pm 15.15
Day29	149.83 \pm 21.45	142.33 \pm 24.10
Day36	160.67 \pm 22.86	152.50 \pm 24.82
Day43	161.67 \pm 32.12	162.33 \pm 25.78
Day50	179.50 \pm 27.41	171.17 \pm 27.07
Day57	189.33 \pm 30.17	177.67 \pm 27.47
Day64	199.00 \pm 34.53	185.83 \pm 29.11
Day71	202.50 \pm 36.42	185.67 \pm 30.48
Day78	208.92 \pm 39.27	193.67 \pm 30.83
Day85	218.00 \pm 38.68	197.67 \pm 30.98

Mean \pm S.D. ; Statistical analysis : no significant difference

Table 3 Sexual behavior of male rats treated with VigRX compared with the control group (8-week treatment)

Group	No. of rats	Latency (seconds)			Frequency (times)		
		Mount	Intromission	Ejaculation	Mount	Intromission	Ejaculation
Control	12	63.07 ± 25.89	246.25 ± 54.14	1231.67 ± 309.44	43.5 ± 8.66	29.25 ± 2.36	1.75 ± 0.96
VigRX 5 mg/ kg/D	12	95.40 ± 38.25	167.50 ± 83.36	1017.50 ± 200.35	39.80 ± 9.50	28.00 ± 4.97	1.50 ± 0.58

Mean ± S.D. ; Statistical analysis : no significant difference

Table 4 Sexual behavior of male rats treated with VigRX compared with the control group (12- week treatment)

Group	No. of rats	Latency (seconds)			Frequency (Times)		
		Mount	Intromission	Ejaculation	Mount	Intromission	Ejaculation
Control	12	126.25 ± 40.93	228.67 ± 55.58	1730.00 ± 49.87	47.00 ± 5.23	27.00 ± 9.56	1.00 ± 0.00
VigRx 15 mg/kg/D	12	122.00 ± 24.40	231.75 ± 87.13	1474.00 ± 149.17*	37.60 ± 9.58	23.00 ± 5.61	1.50 ± 1.00

Mean ± S.D. ; * P < 0.05

Table 5 Sperm density and erect penile size when erection of male rats treated with VigRX compared with the control group (12 - week treatment)

Group	No. of rats	Sperm density (x10 ⁷ / ml)	Erect penile size (mm.)	
			Width	Length
Control	12	20.41 ± 3.30	5.81 ± 0.40	11.36 ± 1.11
VigRX 15 mg/kg/D	12	24.57 ± 3.64**	6.38 ± 0.43**	12.00 ± 0.84

Mean ± S.D. ; ** P < 0.01

Table 6 Effects of VigRX on the intracavernous pressure in rats compared with the control group

Group (14 consecutive days)	No. of rats	Intracavernous pressure (mmHg)
Control	12	58.08 ± 4.60
VigRX 15 mg/kg/D	12	85.75 ± 6.14*

Mean ± S.D. , * P< 0.05

Table 7 The body weight and some organs weight of male rats treated with VigRX compared with the control group (12 - week treatment)

Parameter	Group	
	Control	VigRX 15 mg/kg/D
Number of rats	12	12
Body weight (g)	488.00 \pm 43.63	467.67 \pm 34.32
Penis(mg%)	66.66 \pm 9.65	71.81 \pm 7.86
Testes(mg%)	814.61 \pm 89.97	811.84 \pm 107.07
Epididymis(mg%)	281.01 \pm 23.14	281.01 \pm 23.14
Seminal vesicle(mg%)	253.27 \pm 73.08	271.08 \pm 74.73
Prostate gland(mg%)	71.72 \pm 16.07	84.62 \pm 17.80
Liver(mg%)	3271.31 \pm 167.72	3268.14 \pm 180.61
Kidney(mg%)	585.11 \pm 34.35	607.48 \pm 36.96
Adrenal gland(mg%)	585.11 \pm 34.35	607.48 \pm 36.96
Spleen(mg%)	198.17 \pm 15.22	196.05 \pm 17.24
Pituitary gland(mg%)	2.32 \pm 0.29	2.47 \pm 0.31

Mean \pm S.D.; Statistical analysis : no significant differences

Table 8 Blood chemistry value , some blood parameters and testosterone level in the male rats treated with VigRX15 mg/kg/D compared with the control group (12 - week treatment)

Parameter	Group	
	Control	VigRX 15 mg/kg/D
Glucose (mg/dl)	126.92 \pm 25.89	126.25 \pm 16.21
Blood urea nitrogen (mg/dl)	27.33 \pm 2.42	27.58 \pm 2.50
Creatinine (mg/dl)	0.36 \pm 0.08	0.39 \pm 0.08
Cholesterol (mg/dl)	77.67 \pm 7.63	71.58 \pm 7.69
Triglyceride (mg/dl)	22.70 \pm 9.80	20.57 \pm 14.76
Serum Glutamic Oxaloacetic Transferase (U/L)	85.90 \pm 26.51	108.45 \pm 40.25
Serum Glutamic Pyruvate Transferase (U/L)	59.90 \pm 19.16	54.22 \pm 13.15
Alkaline phosphatase (U/L)	89.00 \pm 15.85	93.17 \pm 20.64
Total protein (g/dl)	5.95 \pm 0.47	5.73 \pm 0.23
Albumin (g/dl)	3.75 \pm 0.13	3.72 \pm 0.12
White blood cell (cells/cumm ³)	2436.36 \pm 490.45	2522.22 \pm 618.02
Hemoglobin (g/dl)	13.80 \pm 1.51	14.42 \pm 0.42
Hematocrit (%)	42.43 \pm 4.78	45.11 \pm 2.27
Red blood cell (mill/ μ l)	7.92 \pm 0.85	8.33 \pm 0.52
Platelet (thsn / μ l)	652.17 \pm 78.17	646.75 \pm 54.74
Polymorphonuclear granular leucocyte (%)	14.67 \pm 9.23	22.20 \pm 8.92
Lymphocytes (%)	83.58 \pm 9.44	74.40 \pm 9.87*
Monocytes (%)	3.00 \pm 0.00	2.38 \pm 1.06
Eosinophils (%)	1.33 \pm 0.50	2.50 \pm 1.22
Mean corpuscular volume (fl)	53.50 \pm 0.52	53.80 \pm 0.92
Mean corpuscular hemoglobin (pico g)	17.43 \pm 0.36	17.23 \pm 0.65
Mean corpuscular hemoglobin concentration (%)	32.37 \pm 0.32	31.97 \pm 0.84
Testosterone (ng / ml)	3.66 \pm 1.10	6.20 \pm 2.57*

Mean \pm S.D. ; * P < 0.05

Table 9 Effects of long term treatment with VigRX on some organ histology of male rats.

Organs	Lesions	Control (n = 12)	VigRX 15 mg/kg /D (NA/TN) (n = 12)
Liver	Fatty degeneration	0/12	0/12
	Hepatocyte megalocytosis	0/12	0/12
	Lymphoid aggregated periportal area	0/12	0/12
	Bile duct proliferation	0/12	1/12
	Peliosis hepatitis	0/12	0/12
Kidney	Multifocal tubular cyst	0/12	0/12
	Tubular cast	0/12	0/12
	Tubulonephrosis	0/12	0/12
Testis	Interstitial edema	0/12	0/12
	Seminiferous tubule degeneration	0/12	0/12
	Congestion	0/12	0/12

NA/TN = the number of animals with pathological abnormalities / the total number of animals examined

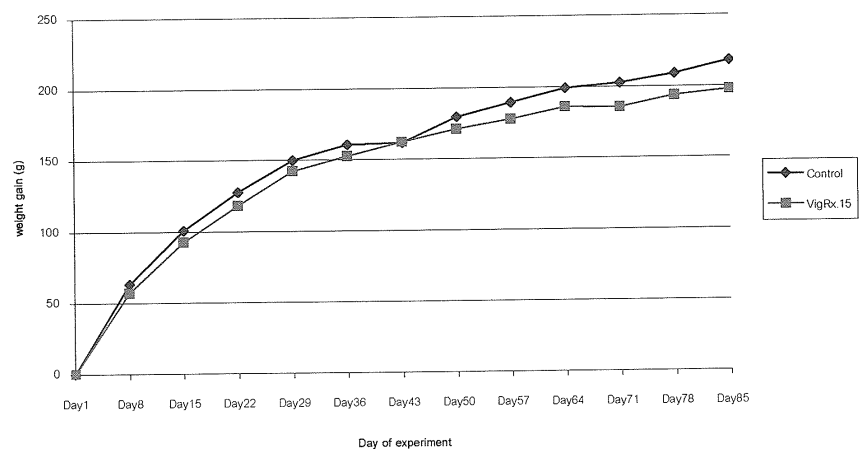


Fig . 1 Long term effects of VigRX 15 mg/kg/D on the body weight gained of the male rats compared with the control group




Fig.2 showed the intromission behavior of the male rat (4-week of treatment)




Fig.3 showed the mounting behavior of the male rat (4-week of treatment)




Fig.4 showed the ejaculation behavior of the male rat (4-week of treatment)

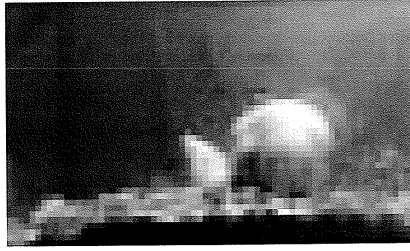


Fig.5 showed the intromission behavior of the male rat (8-week of treatment)

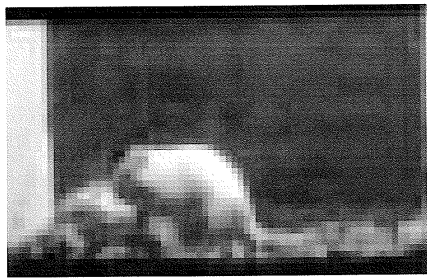


Fig.6 showed the mounting behavior of the male rat (8-week of treatment)

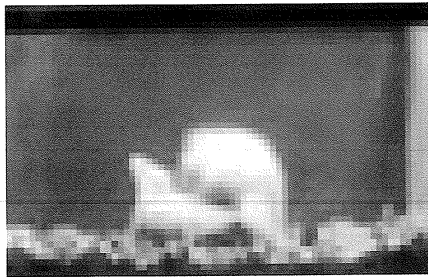


Fig.7 showed the ejaculation behavior of the male rat (8-week of treatment)




Fig.8 showed the intromission behavior of the male rat (12-week of treatment)



Fig.9 showed the mounting behavior of the male rat (12-week of treatment)




Fig.10 showed the ejaculation behavior of the male rat (12-week of treatment)

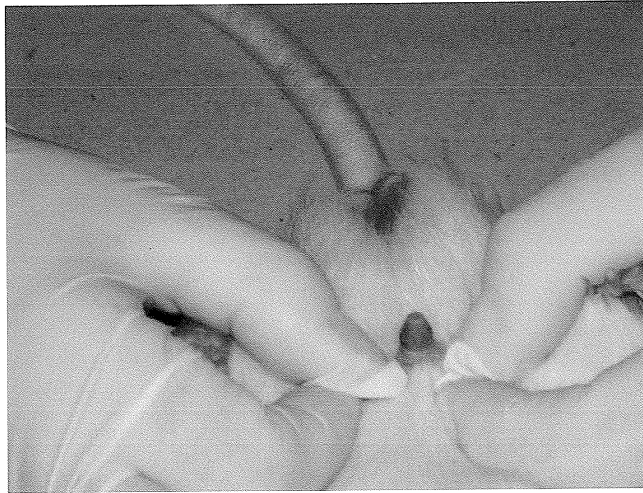

Fig.11 showed the erect penile size of the control rat

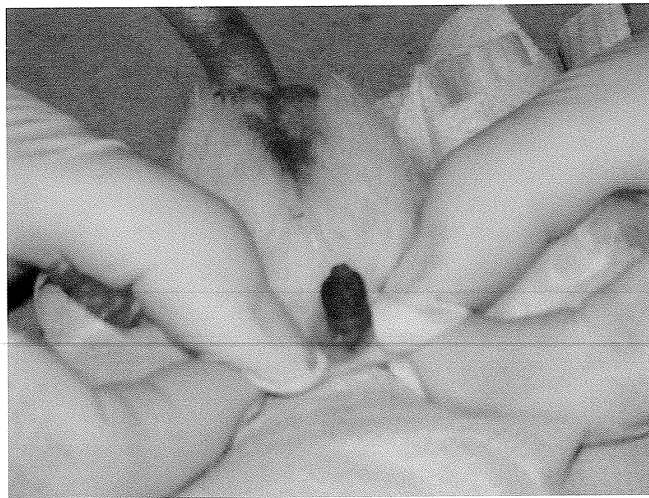

Fig.12 showed the erect penile size of the VigRX – treated rat 1

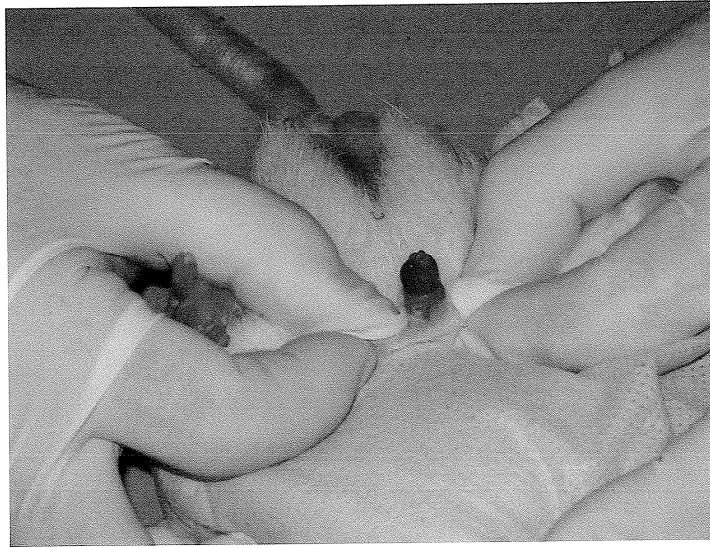


Fig.13 showed the erect penile size of the VigRX – treated rat 2

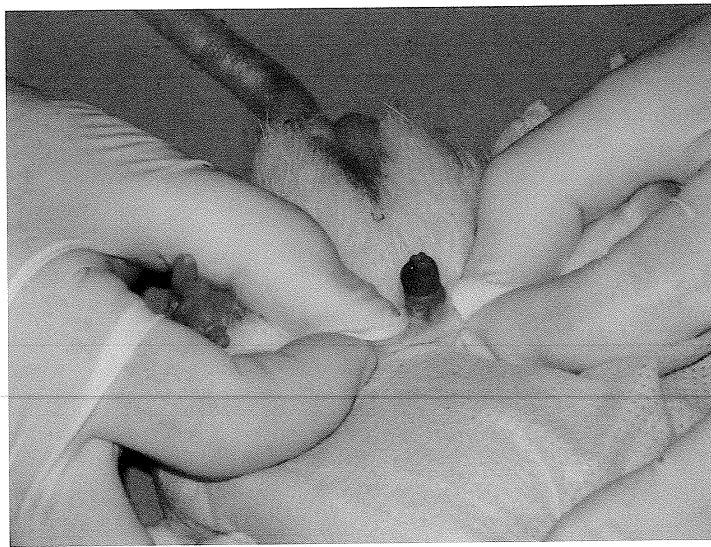
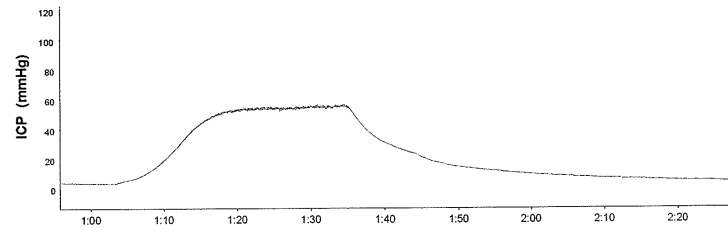


Fig.14 showed the erect penile size of the VigRX – treated rat 3

(A)



(B)

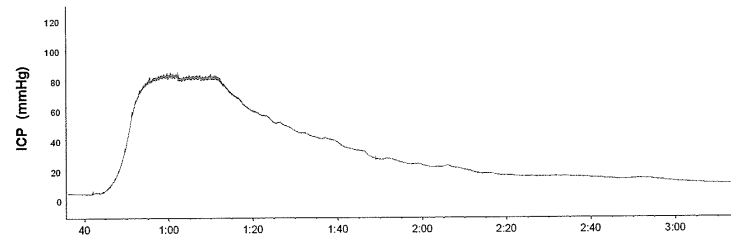


Fig. 15 Representative changes in the ICP recorded from (A) control and (B) VigRX treated rats. Stimulus parameters were 5 volts, frequency of 20 Hertz and duration of 5 milliseconds.

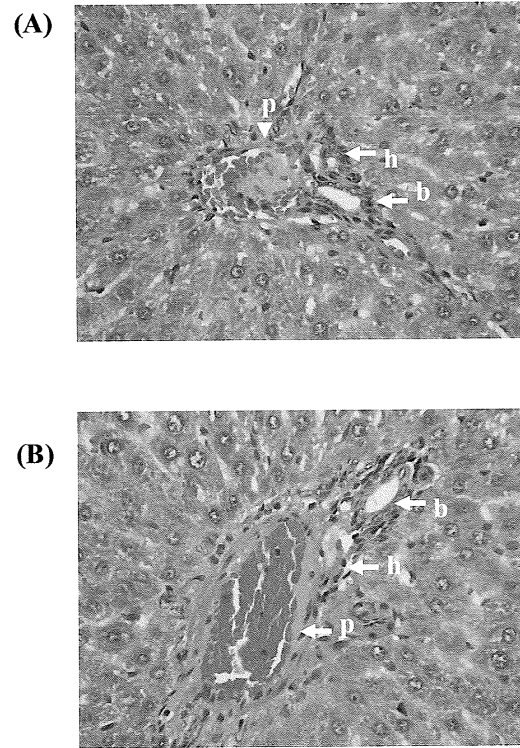


Fig. 16 Liver section from (A) control rat and (B) rat receiving the VigRX at the dosage of 15 mg/kg /D for 12 weeks (H&E staining 40X). p; portal vein, h; hepatic artery, b; bile duct

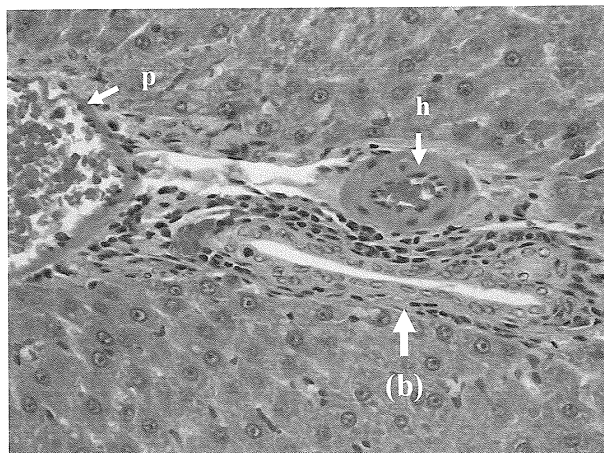


Fig. 17 Histopathological examination of the liver section from the male rat receiving the VigRX at the dosage of 15 mg/kg /D for 12 weeks. An arrow indicated bile duct proliferation (b) (H&E staining 40X). p; portal vein, h; hepatic artery

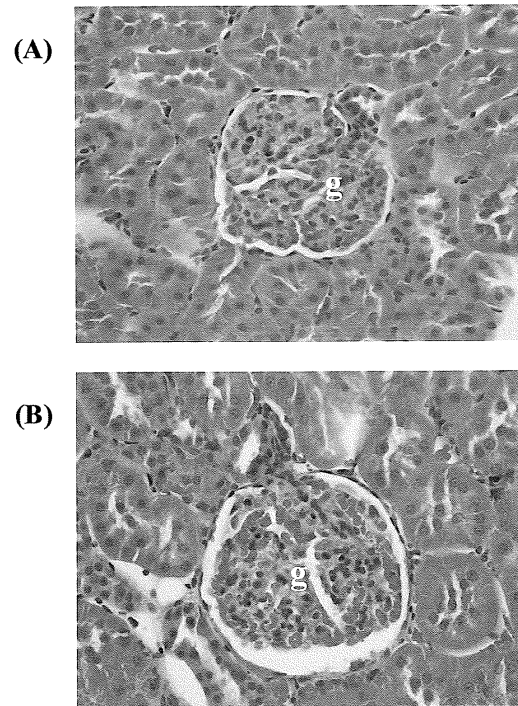
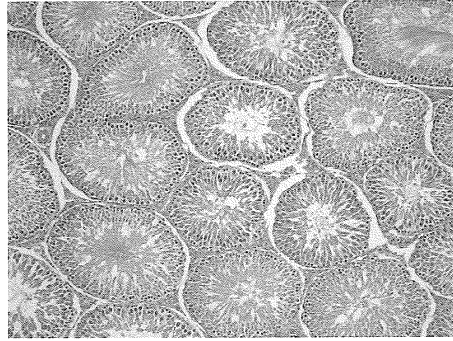


Fig. 18 Kidney section from (A) control rat and (B) rat receiving the VigRX at the dosage of 15 mg/kg /D for 12 weeks (H&E staining 40X). g; glomerulus

(A)



(B)

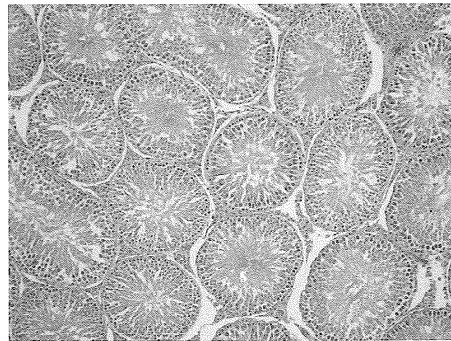
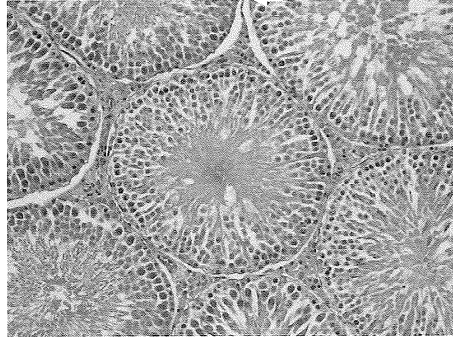


Fig. 19 Testicular section from (A) control rat and (B) a rat receiving the VigRX at the dosage of 15 mg/kg /D for 12 weeks (H&E staining 10X). s; seminiferous tubule

(A)



(B)

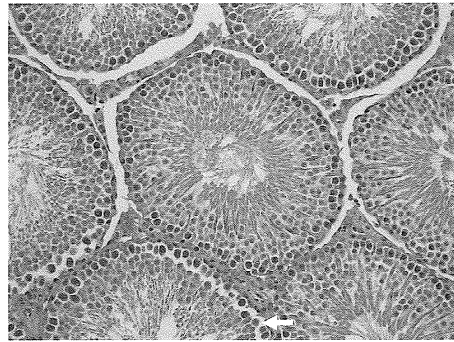


Fig. 20 Testicular sections from (A) control rat and (B) rat receiving the VigRX at the dosage of 15 mg/kg /D for 12 weeks (H&E staining 20X). s; seminiferous tubule, l; Leydig cells (interstitial cells)

Discussion

Long term treatment of VigRX to the male rats every day for 12 weeks had no effect on the body weight gained, this might be good for VigRX because it didn't disturb the body weight.

Long term treatment of VigRX had no effect on sexual behavior of the male rats when VigRX was treated every day for 4, 8 and 12 weeks but the same dosage of VigRX treated to the male rats for only 2 weeks could significantly increase the sexual behavior (Smitasiri et al, 2005). It was possibly that short term treatment of VigRX sometime might be better than long term treatment. In this experiment, we investigated the long term effects of VigRX on the male rats only 4, 8 and 12 – week of treatment. Even though this set of male rat was not the same as the first experiment (VigRX was treated to the male rats for 2 weeks), but the rat was the same strain. Sprague Dawley rat had ever been reported that it was suitable animal model for the study of male behavior (Quinlan et al, 1989).

Studies on long term treatment of VigRX in male rats, we study only VigRX at the dosage of 15 mg/kg/D (calculate from 2 capsules of VigRX /70 kg /D for human use). According to this dose, it seemed to have lesser effect to the rats than higher dose of VigRX i.e. 30 mg /kg/D (calculate from 4 capsules of VigRX /70 kg/D for human use). Then in this experiment, VigRX at the dosage of 15 mg/kg/D sometime may not so effective as VigRX at the dosage of 30 mg/kg/D.

Long term treatment of VigRX could still increase the sperm density, the width of erect penile size and intracavernosal pressure. This suggested that VigRX might have its main effects on the blood flow especially by increasing of blood flow to the penis and testes. These effects of VigRX like *Butea superba* because it could increase the sperm density, intracavernosal pressure and penile enlargement like VigRX also. (Smitasiri et al, 2003).

VigRX had no effect on every organ weight , blood chemistry , some blood parameters. This showed that VigRX had no side effect on all of the organs studied and blood parameters .

Determination of testosterone level showed that long term treatment of VigRX could significantly increase the testosterone level . The increasing level of testosterone did not relate with the sexual behavior with prostate gland and seminal vesicle weights of these rats. In general , the prostate gland and seminal vesicle were the target organs of testosterone (Zarrow et al , 1964) if the testosterone increase then the prostate gland and seminal vesicle might increase their weights also because this testosterone was its endogenous testosterone but the weight of both prostate gland and seminal vesicle did not significantly increase . According to these results , we must aware about the effects of VigRX on the prostate gland also . Short term treatment of VigRX had no effect on the testosterone level but long term treatment of VigRX could increase testosterone level , this suggested that VigRX might use for improvement of erectile function , erect penile size and sex drive by using VigRX for short term treatment better than long term treatment .

Results from histopathological section of liver , kidney and testes revealed that VigRX had no pathological effects . These results reflected that long term treatment of VigRX seemed to be save. These results are very interesting because it was previously reported that treatment of VigRX everyday for 2 weeks had some effects on liver and kidney by decreasing both organs weight significantly and this repeated study still found that VigRX could significantly decrease only the liver weight . Histopathological section of both liver and kidney in this repeated study showed that there was no pathological sign in both organs. These results will support that VigRX seemed to be the save herbal product because VigRX could induce the erect penile size but had no pathological effects.

Conclusion

Long term treatment of VigRX at the dosage of 15 mg / kg / D for 4 , 8 and 12 weeks had no effect on body weight gained and could not induce sexual behavior in the male rats. But long term treatment of VigRX could significantly increase the width of erect penile size , sperm density , intracavernosal pressure and testosterone level but had no effects on every organs weight , blood chemistry , some blood parameters in the male rats . Histopathological section of some organs i.e. liver , kidney and testes showed that there was no pathological effects on all of these organs.

References

1. Ang, H.H. and Ngai , T.H. 2001. Aphrodisiac evaluation in non-copulator male rats after chronic administration of *Eurycoma longifolia* Jack. Fundam. Clin. Pharmacol. ,15(4):265-8.
2. Antunes, E.,Gordo,W.M. and Oliveira, J.F. 2001. The relaxation of isolated rabbit corpus cavernosum by the herb medicine *Catuama* (ginger herb, muira puama,and others) and its constituents. Phytother. Res. ,15(5):416-21.
3. Anusarnsunthorn, L. 1931. Kwao Keur Tuberous Roots Drug Pamphlet. Upatipong Press, Chiang Mai, p.17.
4. Carro-Juarez, M., Cervantes, E., Cervantes-Mendez ,M., Rodriquez-Manso, G. 2004. Aphrodisiac properties of *Montanoa tomentosa* aqueous crude extract in male rats. Pharmacol. Biochem. Behav., 78(1):129-34.
5. Dhawan, K., Kumar, S. and Sharma, A. 2003. Aphrodisiac activity of methanol extract of leaves of *Passiflora incarnata* Linn. (passion flower) in mice. Phytother. Res., 17(4):401-3.
6. Gauthaman, K. and Adaikan, P.G. 2005. Effect of *Tribulus terrestris* on nicotinamide adenine dinucleotide phosphate-diaphorase activity and androgen receptors in rat brain. J.Ethnopharmacol., 96(1-2):127-32.
7. Islam , M.W. , Tariq , M. , Ageel , A.M. , Al - Said , M.S. and Al - Yhya , A.M. 1991. Effects of *Salvia haematodes* on sexual behavior of male rats. J. Ethnopharmacol., 33: 67 -72.

8. Kheowmung, B., Yodkumpun, p., Manoruang, V., and Smitasiri, Y. 1992. Effects of Some Medicinal Plants in Chicks Compared with Androgen. 18th Congress on Science and Technology of Thailand, Queen Sirikit National Convention Center, Bangkok, pp. 180-181.
9. Pimongkhongul, S. 2001. Comparison of the Effects of Red Kwao Keur (*Butea superba* Roxb.) from Two Different Areas on Reproductive Organs, Reproductive Behavior and Penile Erection in Male Albino Rats. M.S. Thesis (Environmental Biology), Suranaree University of Technology, Nakhon Ratchasima, p.159.
10. Quinlan, D.M., Nelson, R.J., Partin, A.W., Mostwin, J.L., and Walsh, P.C. 1989. The Rat as a Model for the Study of Penile Erection. *J. Urol.*, 141: 656-661.
11. Ramachandran, S., Sridhar, Y., Sam, S.K., Saravana, M., Leonard, J.T., Anbalagan, N. and Sridhar, S.K. 2004. Aphrodisiac activity of *Butea frondosa* Koen. ex Roxb. Extract in male rats. *Phytomedicine*, 11(2-3):165-8.
12. Smitasiri, Y., Anuntalabhochai, S., Ingkaninan, K., Tocharus, C., Pimongkhongul, S., Manasathien, A., Pisutthanan, S., Jeenapongsa, R., and Lertprasertsuke, N. 2003. Red Kwao Keur Research Project and Development: Phase 1. Final Report, School of Science, Mae Fah Luang University, Chiang Rai, p.146.
13. Tajuddin, A.S., Ahmad, S., Latif, A. and Qasmi, I.A. 2004. Aphrodisiac effect of 50% ethanolic extract of *Syzygium aromaticum* (L.) Merr. & Perry. (clove) on sexual behaviour of normal male rats. *BMC Complement Altern. Med.*, 4(1):17.

14. Tocharus, C., Smitasiri, Y., Ingkaninan, K., Pisutthanan, S., and Jeenapongsa, R. 2002. Effects of *Butea superba* Roxb. on Intracavernous Pressure in Rats. Abstract, 1st Graduate Research Symposium, The Pharmaceutical Education Development Consortium, Faculty of Pharmaceutical Science, Naresuan University, Phitsanulok, pp. 1-8.
15. Zarrow, M.X., Yochim, J.M., McCarthy, J.L. and Sanborn R.C. 1964. Experimental Endocrinology : A sourcebook of basic techniques. Academic Press, New York, 519 pp.

